



LEEDS  
BECKETT  
UNIVERSITY

---

Citation:

Kadwani, O and Price, OJ and Kemp, SV and Quarto, C and Hull, JH (2019) A vascular cause of unexplained exertional wheeze : Keeping a high index of suspicion. *Respiratory Medicine Case Reports*, 29. ISSN 2213-0071 DOI: <https://doi.org/10.1016/j.rmcr.2019.100993>

Link to Leeds Beckett Repository record:

<https://eprints.leedsbeckett.ac.uk/id/eprint/6465/>

Document Version:

Article (Published Version)

---

Creative Commons: Attribution-Noncommercial-No Derivative Works 4.0

The aim of the Leeds Beckett Repository is to provide open access to our research, as required by funder policies and permitted by publishers and copyright law.

The Leeds Beckett repository holds a wide range of publications, each of which has been checked for copyright and the relevant embargo period has been applied by the Research Services team.

We operate on a standard take-down policy. If you are the author or publisher of an output and you would like it removed from the repository, please [contact us](#) and we will investigate on a case-by-case basis.

Each thesis in the repository has been cleared where necessary by the author for third party copyright. If you would like a thesis to be removed from the repository or believe there is an issue with copyright, please contact us on [openaccess@leedsbeckett.ac.uk](mailto:openaccess@leedsbeckett.ac.uk) and we will investigate on a case-by-case basis.



# A vascular cause of unexplained exertional wheeze: Keeping a high index of suspicion

Owais Kadwani<sup>a</sup>, Oliver J. Price<sup>b</sup>, Samuel V. Kemp<sup>a</sup>, Cesare Quarto<sup>c</sup>, James H. Hull<sup>a,\*</sup>

<sup>a</sup> Department of Respiratory Medicine, Royal Brompton Hospital, London, UK

<sup>b</sup> Institute of Sport, Physical Activity and Leisure, Respiratory Health Research Group, Leeds Beckett University, Leeds, UK

<sup>c</sup> Department of Cardiac Surgery, Royal Brompton Hospital, London, UK

## ARTICLE INFO

### Keywords:

Dyspnoea  
Cough  
Trachea  
Wheeze  
Bronchoscopy

## ABSTRACT

A 31-year-old female was referred with a history of unexplained exertional breathlessness. The patient had normal resting lung function and a CT thorax showed no significant abnormality. Closer scrutiny of the flow-volume loop confirmed an elevated Empey's index. Cardiopulmonary exercise testing with continuous laryngoscopy was conducted to evaluate the upper airway response to exercise which confirmed loud biphasic wheeze. A bronchoscopy revealed no stenosis nor intraluminal narrowing, however, a contrast CT confirmed a right-sided aortic arch and aberrant left subclavian artery. Following multidisciplinary review, the patient opted for a surgical approach to treatment however despite initially reporting an improvement in symptoms and exercise capacity continued to suffer exertional wheeze two-years post-surgery. This clinical report describes a rare vascular cause of exertional wheeze but also provides a cautionary note in terms of providing a guarded prognosis for adults undergoing surgical intervention for tracheal compression arising from congenital vascular abnormalities.

## 1. Introduction

Respiratory symptoms are frequently reported by young athletic individuals, however detecting the cause is often challenging due to the limited value of patient self-report and broad differential diagnosis [1, 2]. In most instances, individuals presenting with exertional wheeze are prescribed an efficacy trial of inhaler therapy for presumed exercise-induced asthma - a condition characterised by temporary lower airway narrowing [2]. It is now recognised however that the structural and functional behaviour of the upper and large airways during exercise are equally important and thus employing a systematic approach to clinical assessment (i.e. considering the total airway) is required to secure a diagnosis [3].

## 2. Case presentation

A 31-year-old non-smoking athletic female was referred with a six-year history of unexplained exertional breathlessness associated with an audible wheeze. She described a sensation akin to "breathing through a straw" during strenuous exercise but also a rapid, spontaneous recovery on exercise cessation. Her past medical history included

childhood-onset atopic asthma, treated with low dose inhaled corticosteroid and bronchodilator treatment. She denied resting or nocturnal symptoms and her exercise-induced respiratory symptoms did not respond to an escalation of standard asthma therapy.

Baseline investigations revealed normal resting lung function: forced expiratory volume 1 (FEV<sub>1</sub>) 3.3L (108% predicted), forced vital capacity (FVC) 4.3L (122% predicted) [4]. Resting fractional exhaled nitric oxide (marker of eosinophilic airway inflammation) was also within normal limits (13 ppb) [5]. A methacholine bronchial provocation challenge demonstrated no evidence of airway hyper-responsiveness [6] and a CT thorax was reported as showing no significant abnormality. Closer scrutiny of her spirometric flow-volume loop revealed a significant reduced peak expiratory flow rate (PEFR), 258 L/min, whilst her FEV<sub>1</sub> was normal at 3.3 L, giving a flattened appearance to the expiratory phase (Fig. 1) and an elevated Empey's index.

Treadmill cardiopulmonary exercise testing (CPET) with continuous laryngoscopy, the 'gold-standard' test for exercise induced laryngeal obstruction (EILO) was subsequently conducted to evaluate the upper airway response to exercise [7]. This confirmed her history of loud biphasic wheeze when running vigorously, a supra-normal peak exercise capacity (156% predicted) but no evidence of significant EILO. A

\* Corresponding author. Department of Respiratory Medicine, Royal Brompton Hospital, London, SW3 6NP, United Kingdom.

E-mail address: [j.hull@rbht.nhs.uk](mailto:j.hull@rbht.nhs.uk) (J.H. Hull).

bronchoscopy with dynamic manoeuvres was subsequently undertaken for assessment of the subglottic airway. This revealed no stenosis nor intraluminal narrowing but prominent vascular pulsation, visible at the posterior tracheal wall. At this stage no satisfactory cause was identified for the patient's exertional symptoms which raised the following questions: (a) how can Empey's index be applied to guide further investigation? (b) what is the treatment of choice for vascular abnormalities compressing the trachea during exercise?

### 3. Discussion

Empey's index was first described by Professor Duncan Empey in 1972, as the ratio between FEV<sub>1</sub> (ml) and PEF (L/min) [8,9], values above 10 suggest upper airway obstruction and thus the patient's index of 12.8 (3300/258) is in-keeping with pathology of the upper/large airways. Despite the reassuring bronchoscopic appearance, a contrast CT thorax was arranged. This revealed a right-sided aortic arch and aberrant left subclavian artery arising from the descending arch (Fig. 2). This so-called Kommerel diverticulum with a remnant ligamentum arteriosum formed a vascular ring causing tracheal compression; a congenital vascular anomaly estimated to occur in only 0.05% of the population. In this case we hypothesize that the dynamic state of vigorous exercise, with heightened ventilation and cardiac output likely results in further tracheal compression, dyspnoea and wheeze.

Following multidisciplinary team discussion and surgical risk review, the patient opted for a surgical approach to treatment. This entailed dissecting the vascular ring, aortic arch reconstruction and transposition of the left subclavian artery to the left carotid artery. Previous studies have described successful outcomes and symptomatic improvement in 97% of patients following surgery [10]. Despite initially

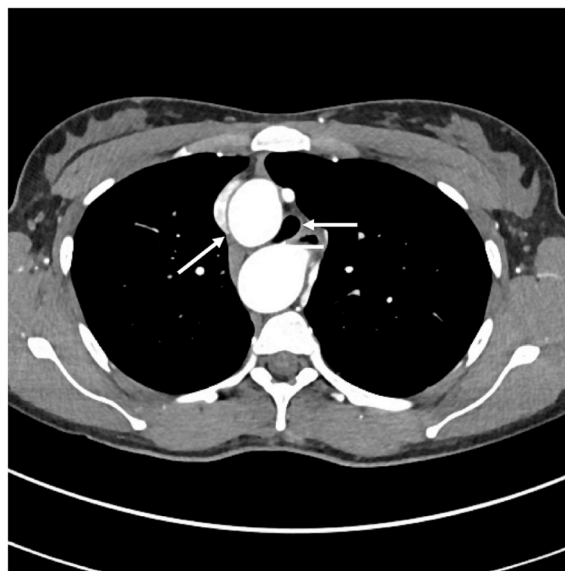

Fig. 2. CT thorax with contrast demonstrating tracheal compression by vascular structures (short arrow indicating tracheal lumen; long arrow indicating right sided aortic arch at level T4; axial view).

reporting an improvement in symptoms and exercise capacity; the patient continued to suffer troublesome exertional wheeze two-years post-surgery. Furthermore, the patients flow-volume loop appearance and Empey's index and CT appearance remained unchanged, suggesting

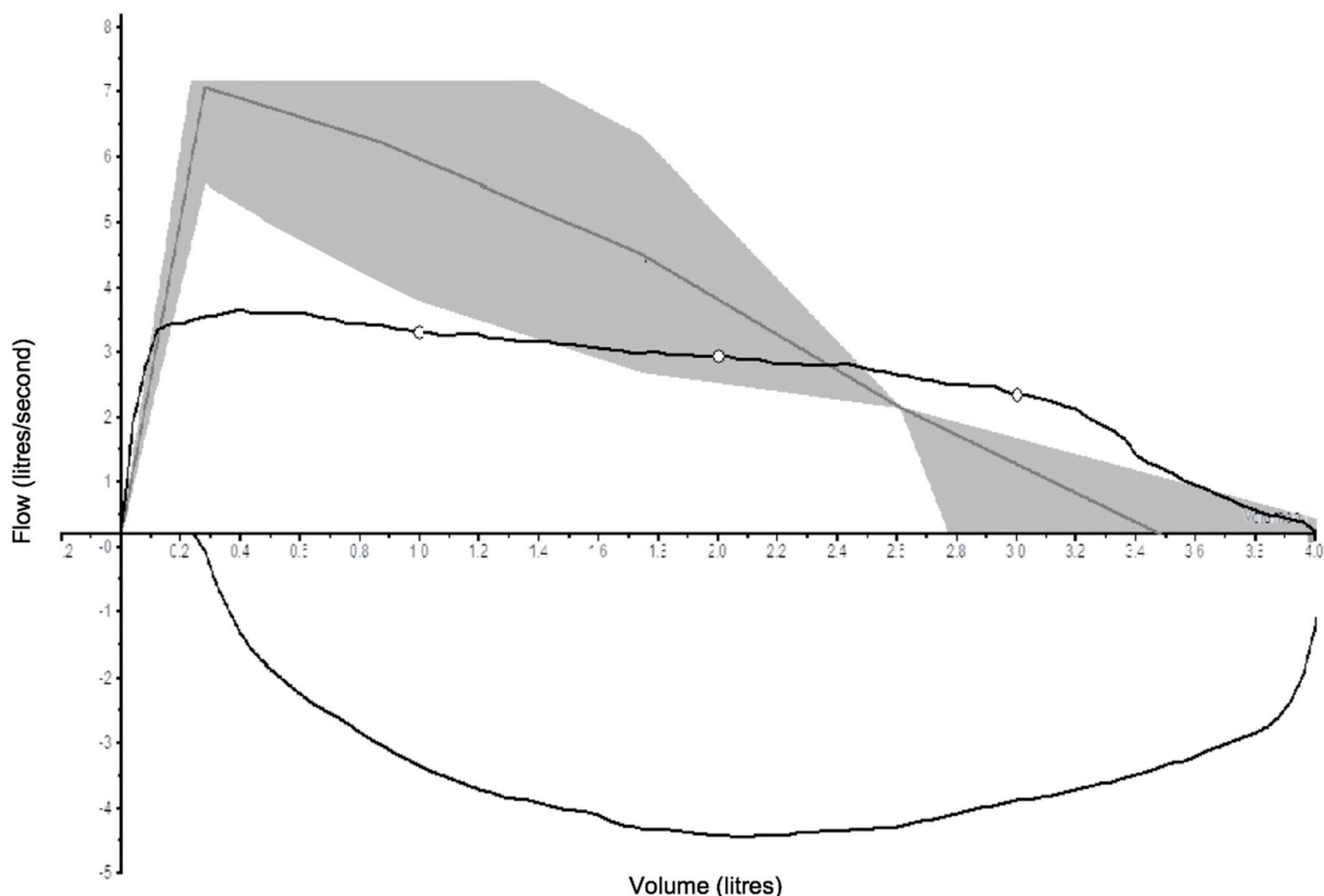


Fig. 1. Spirometry flow-volume loop demonstrating a 'flattened' appearance of the expiratory phase and reduced peak expiratory flow rate.

the malacic airway segment was chronically damaged by the long-standing vascular compression.

#### 4. Conclusion

A persistently abnormal flow-volume loop appearance and elevated Empey's index should act to prompt consideration of an upper airway cause for breathing difficulties in patients presenting with exertional breathlessness. This clinical report describes a rare vascular cause of exertional wheeze but also provides a cautionary note in terms of providing a guarded prognosis for adults undergoing surgical intervention for tracheal compression arising from congenital vascular abnormalities.

#### Author contribution statement

All authors were involved in the conception of the case study, drafting and critical revision of manuscript, and final approval of the version to be published.

#### Declaration of competing interest

The authors have no real or perceived conflict of interest in respect of this manuscript.

#### References

- [1] O.J. Price, J.H. Hull, L. Ansley, M. Thomas, C. Eyles, Exercise-induced bronchoconstriction in athletes - a qualitative assessment of symptom perception, *Respir. Med.* 120 (2016) 36–43.
- [2] J.H. Hull, Not all wheeze is asthma: time for patients to exercise their rights, *Thorax* 70 (1) (2015) 7–8.
- [3] O.J. Price, E.S. Walsted, J.H. Hull, Understanding the total airway response to exercise: current perspectives and future challenges, *Current Opinion in Physiology* 10 (2019) 185–192.
- [4] B.L. Graham, I. Steenbruggen, M.R. Miller, I.Z. Barjaktarevic, B.G. Cooper, G. L. Hall, et al., Standardization of spirometry 2019 update. An official American thoracic society and European respiratory society technical statement, *Am. J. Respir. Crit. Care Med.* 200 (8) (2019) e70–e88.
- [5] R.A. Dweik, P.B. Boggs, S.C. Erzurum, C.G. Irvin, M.W. Leigh, J.O. Lundberg, et al., An official ATS clinical practice guideline: interpretation of exhaled nitric oxide levels (FENO) for clinical applications, *Am. J. Respir. Crit. Care Med.* 184 (5) (2011) 602–615.
- [6] A.L. Coates, J. Wanger, D.W. Cockcroft, B.H. Culver, Z. Diamant, G. Gauvreau, et al., ERS technical standard on bronchial challenge testing: general considerations and performance of methacholine challenge tests, *Eur. Respir. J.* 49 (5) (2017).
- [7] T. Halvorsen, E.S. Walsted, C. Bucca, A. Bush, G. Cantarella, G. Friedrich, et al., Inducible laryngeal obstruction: an official joint European Respiratory Society and European Laryngological Society statement, *Eur. Respir. J.* 50 (3) (2017).
- [8] D.W. Empey, Assessment of upper airways obstruction, *Br. Med. J.* 3 (5825) (1972) 503–505.
- [9] D. Empey, Patterns of airflow in upper airways obstruction, *Thorax* 27 (2) (1972) 262.
- [10] N. Saran, J. Dearani, S. Said, B. Fatima, H. Schaff, T. Bower, et al., Vascular rings in adults: outcome of surgical management, *Ann. Thorac. Surg.* 108 (4) (2019) 1217–1227.